

# Endoscopically Assisted CTR (EACTR).

**Freih Odeh Abu Hassan**  
**F.R.C.S.(Eng.), F.R.C.S.(Tr.& Orth.)**  
**Professor.of Orthopaedics**  
**Jordan University**

# **62 patients**

- \* 76 Hand.**
- \* 58 Female/ 4 Male.**
- \* Age : 26 – 67 Y.**

# Associated problems

* DM	32
* Gout	02
* Hypertension	08
* Previous Open CTR	09

# Affected Hand

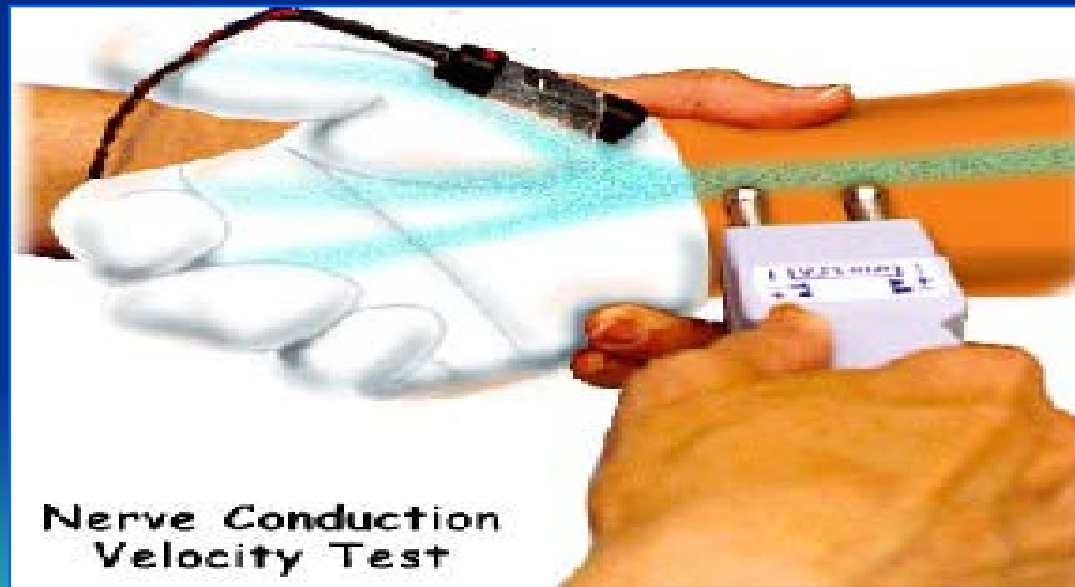<b>*</b>	<b>Bilat.</b>	<b>14</b>
<b>*</b>	<b>Right</b>	<b>42</b>
<b>*</b>	<b>Lt.</b>	<b>06</b>

# Duration of symptoms

1.2 year (6m - 8y)

# Diagnosis

\* 61 hand



# Clinical Dx

**15 hands.**

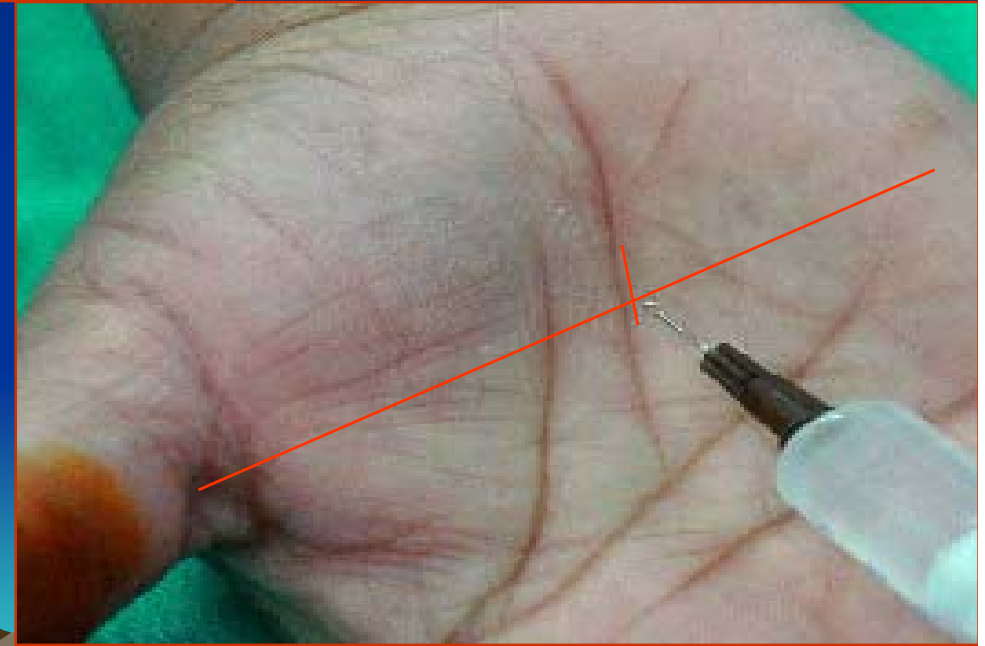
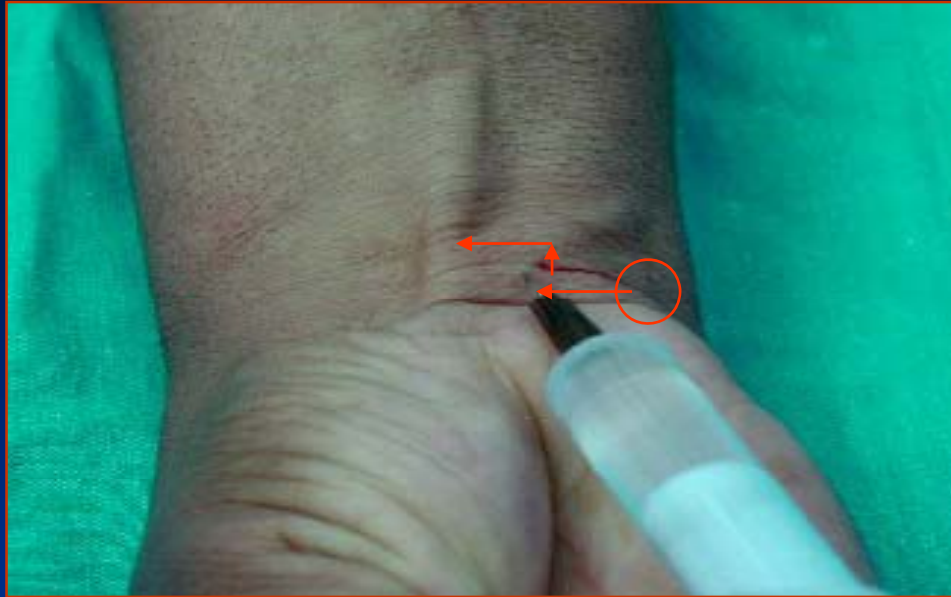
- Compression test.**
- Phalen's test.**

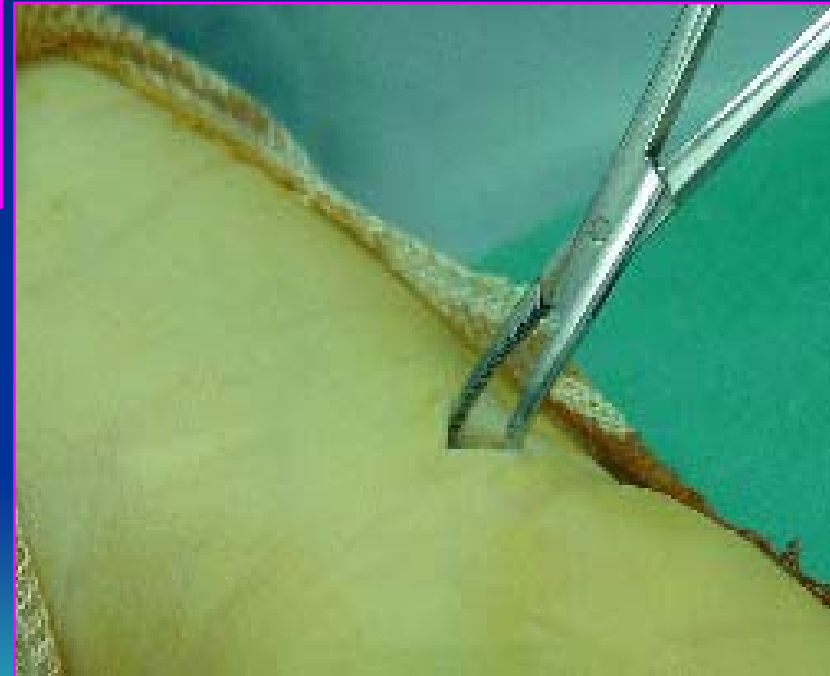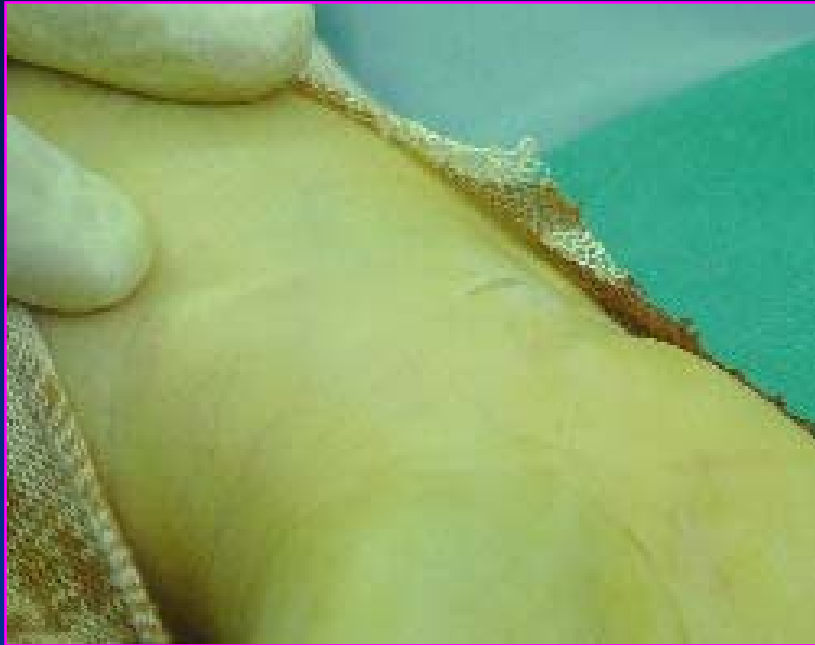# Surgical Technique

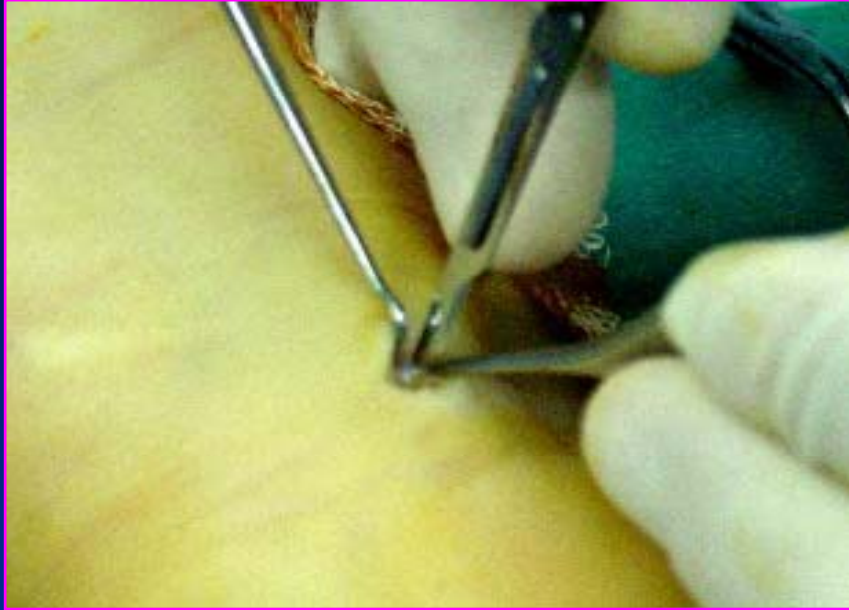


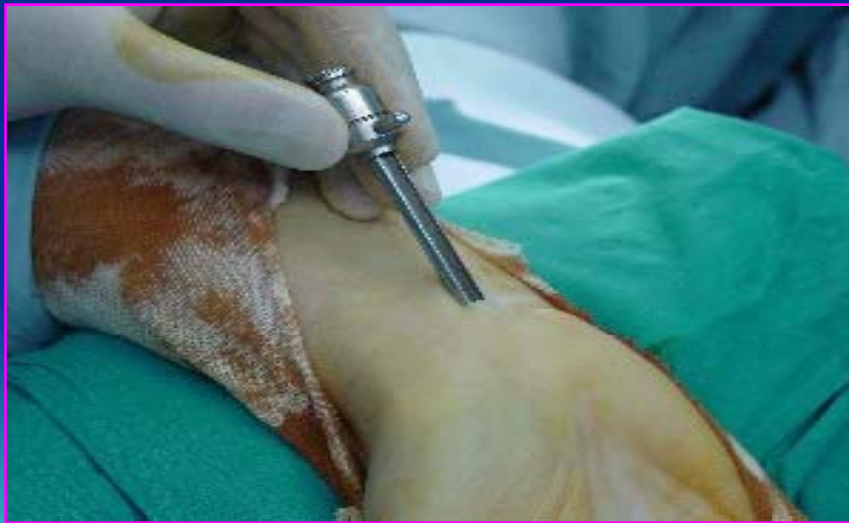
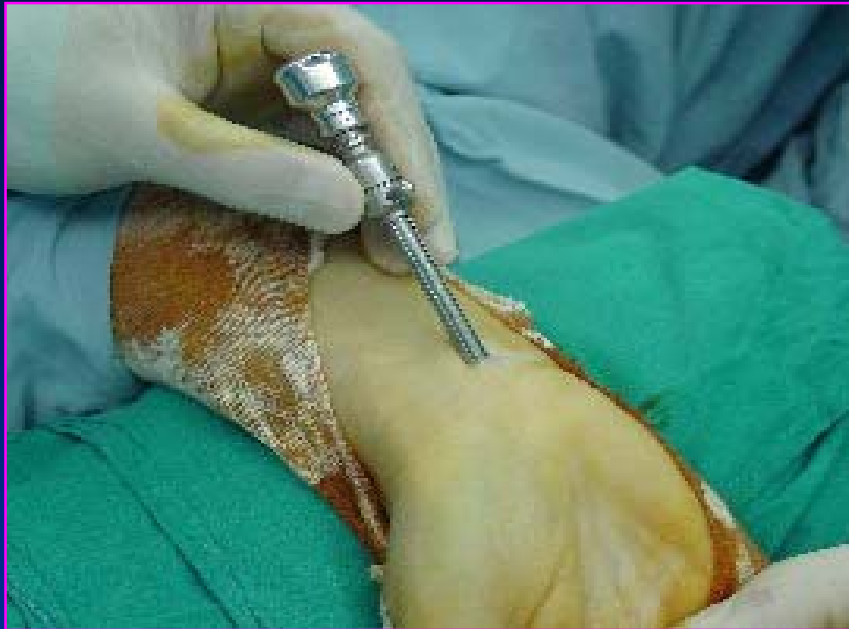# Anaesthesia

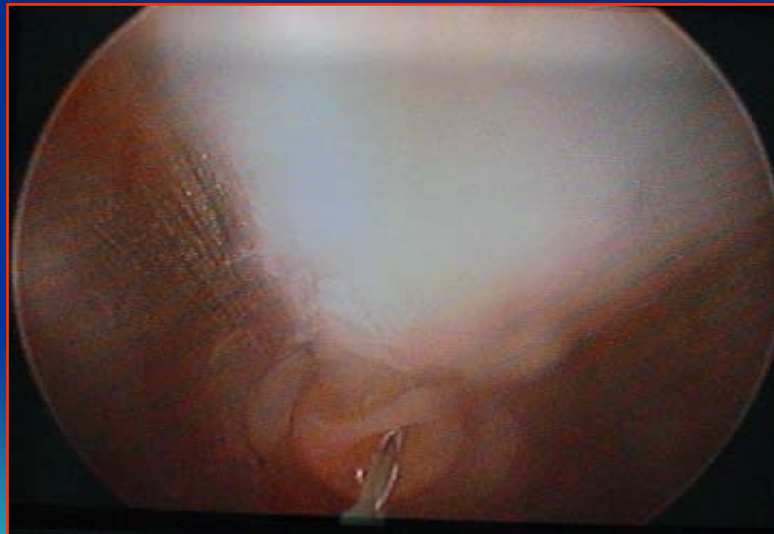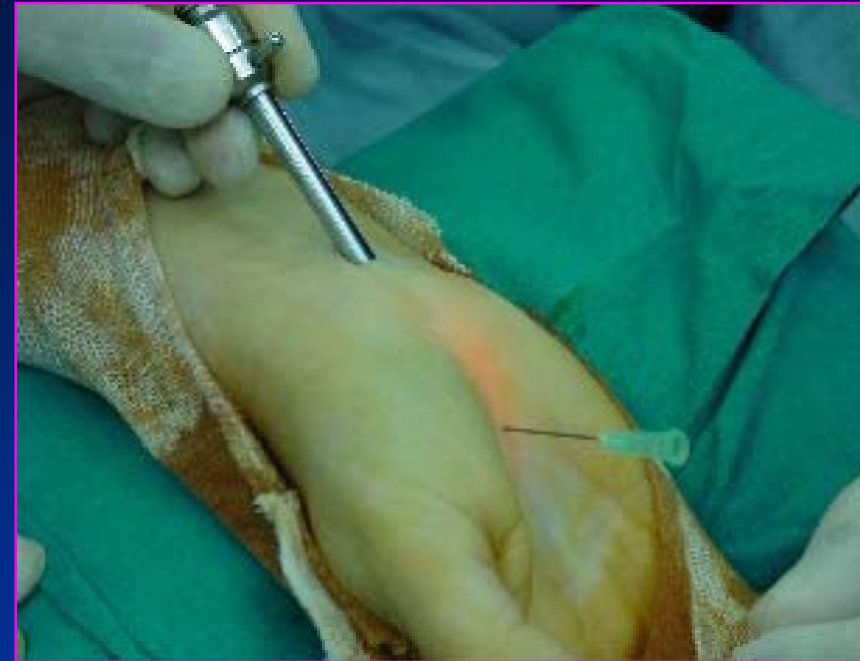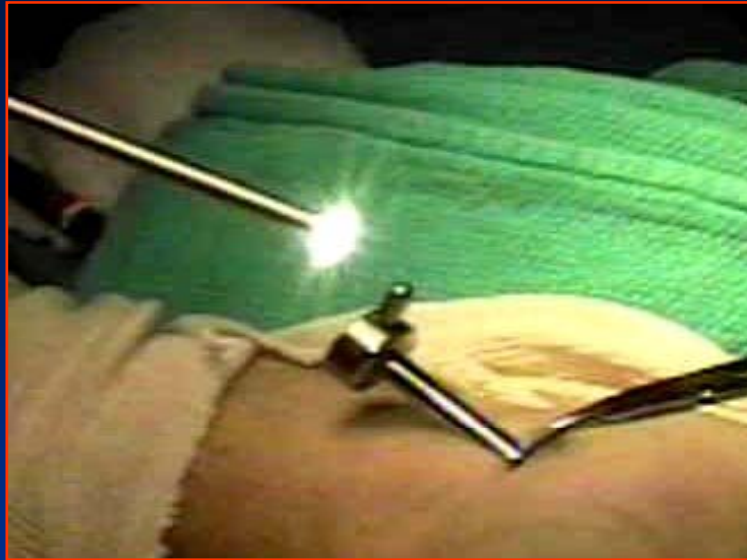- \* **Local An. 22 hand**
- \* **General An. 54 hand**
- \* **Tourniquet all**

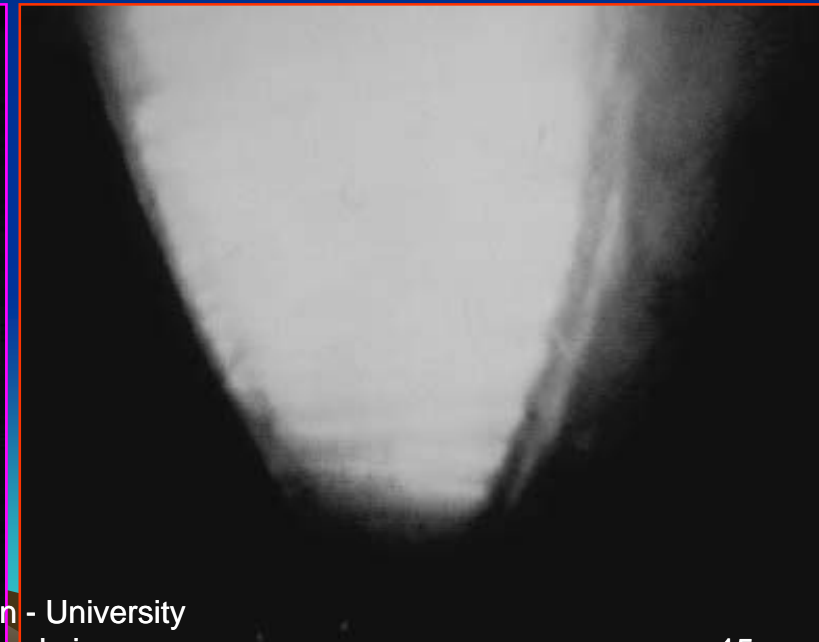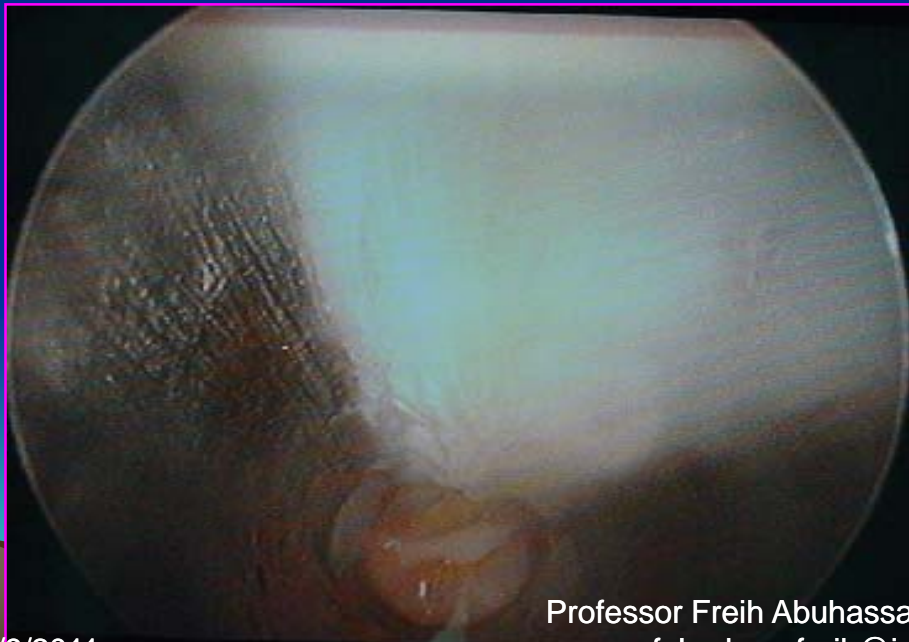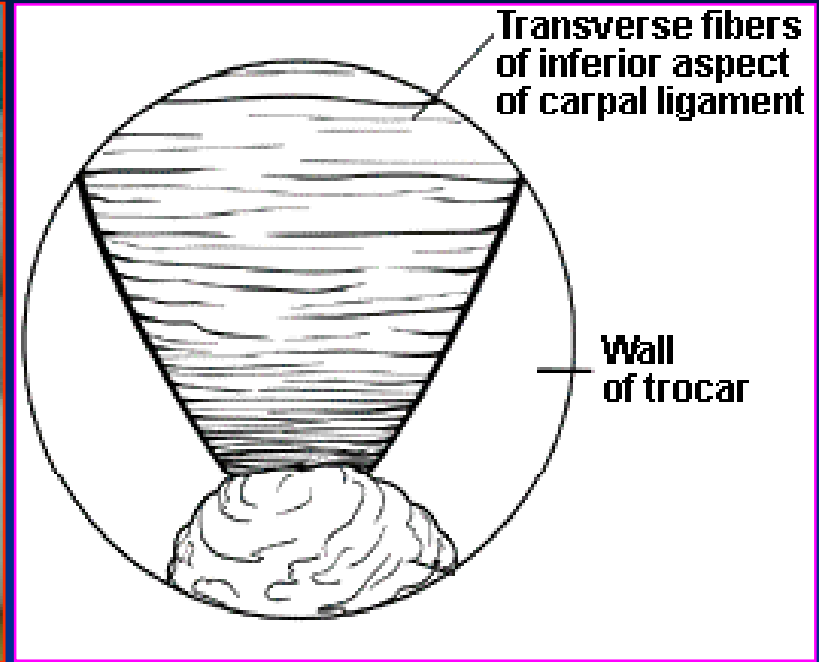


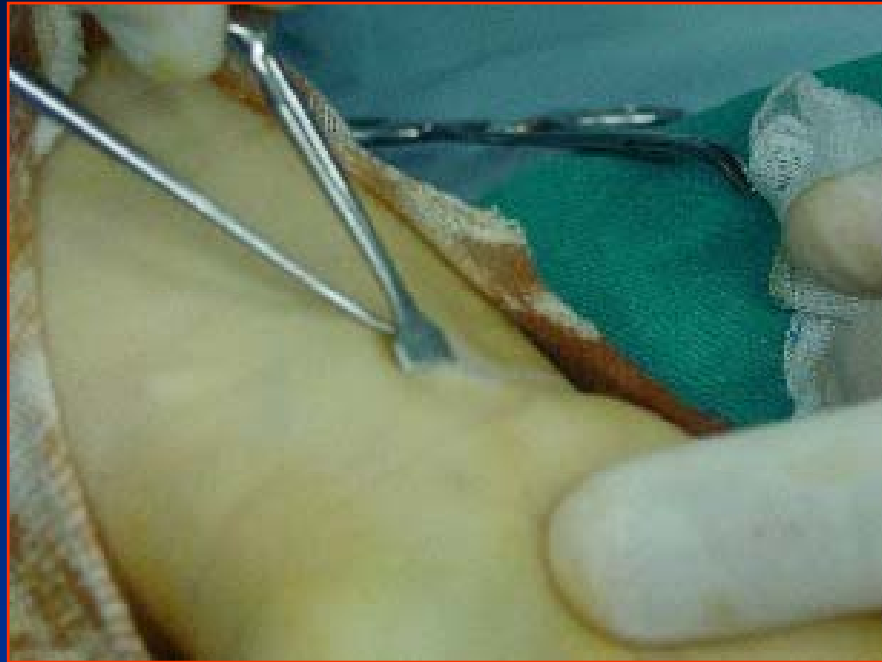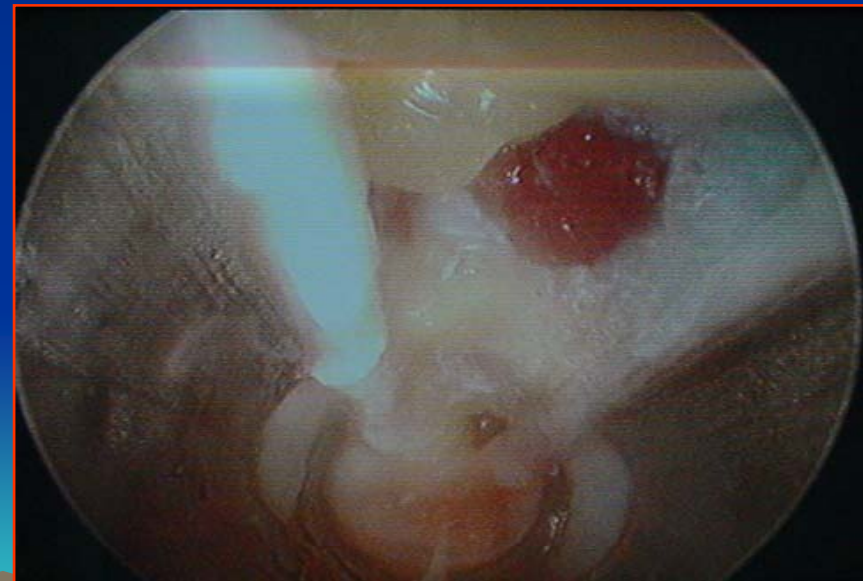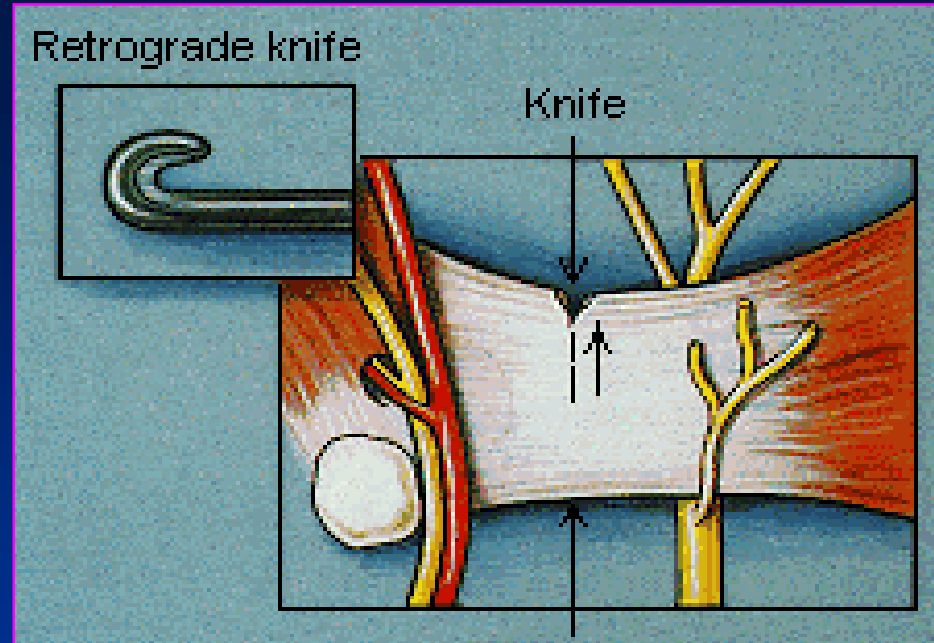




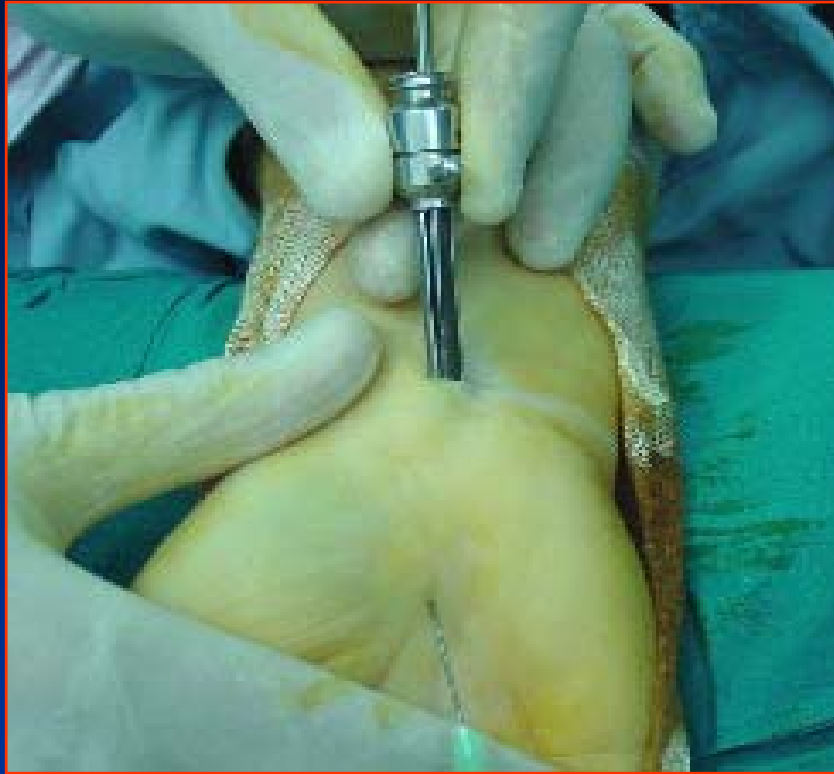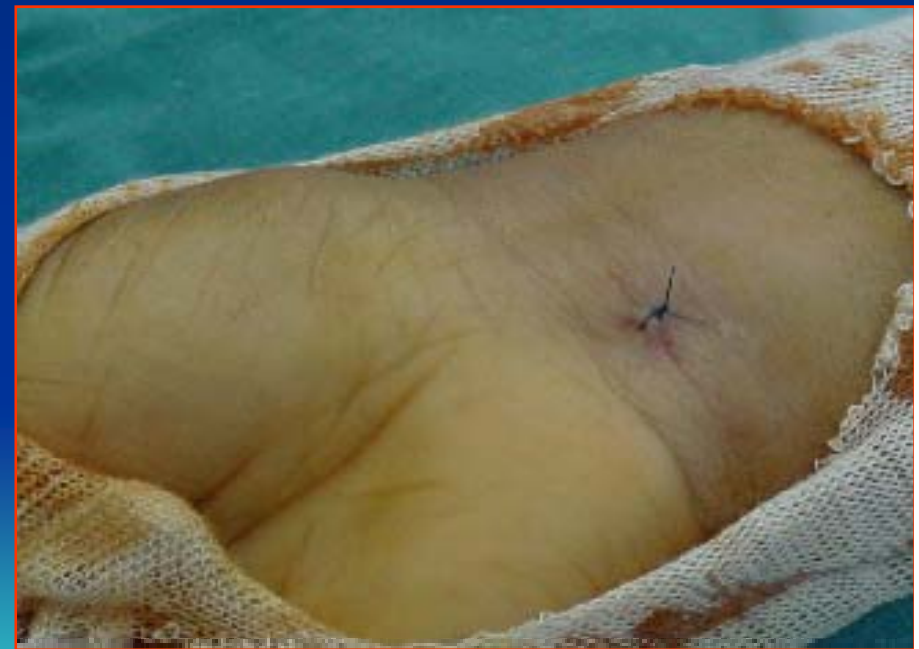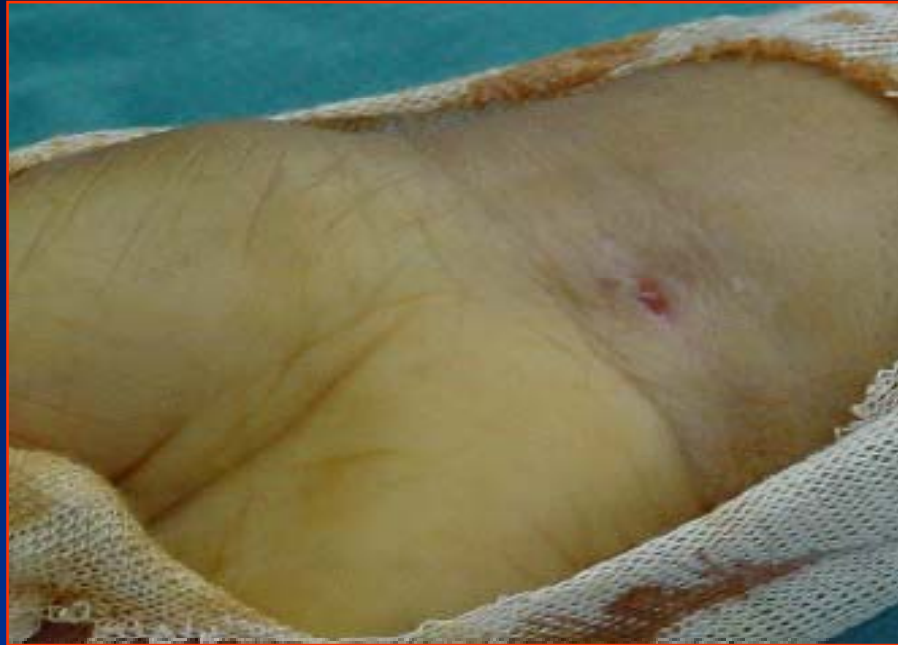










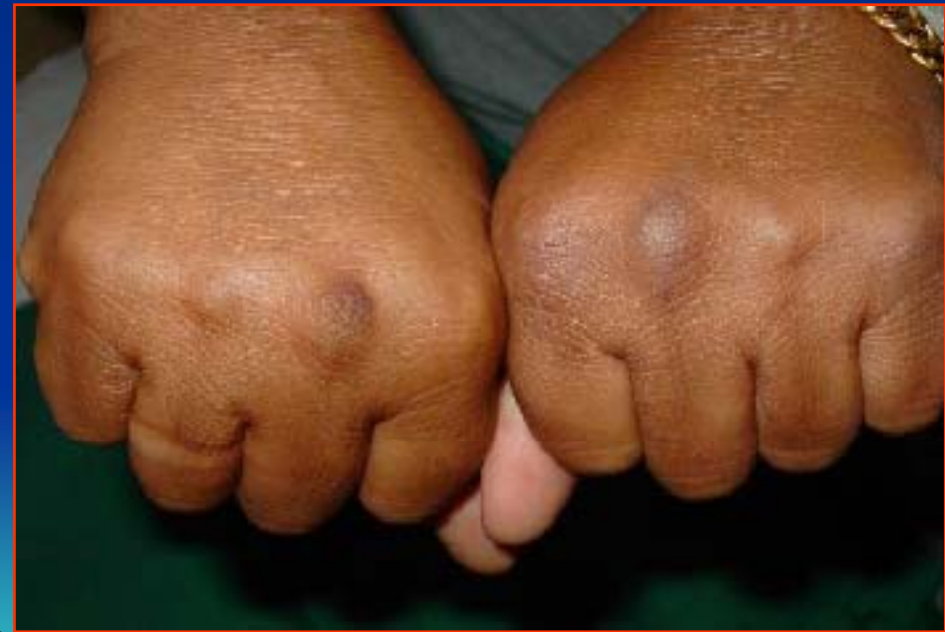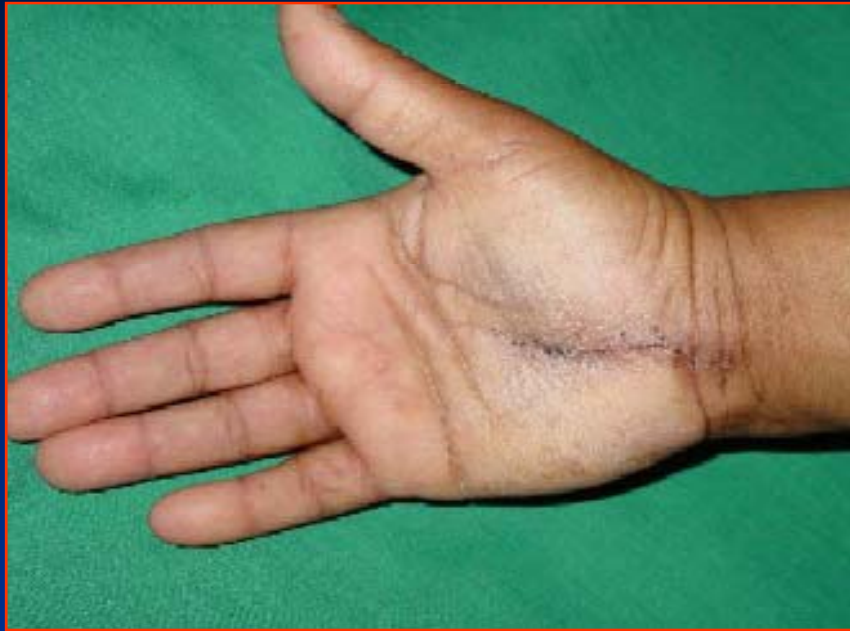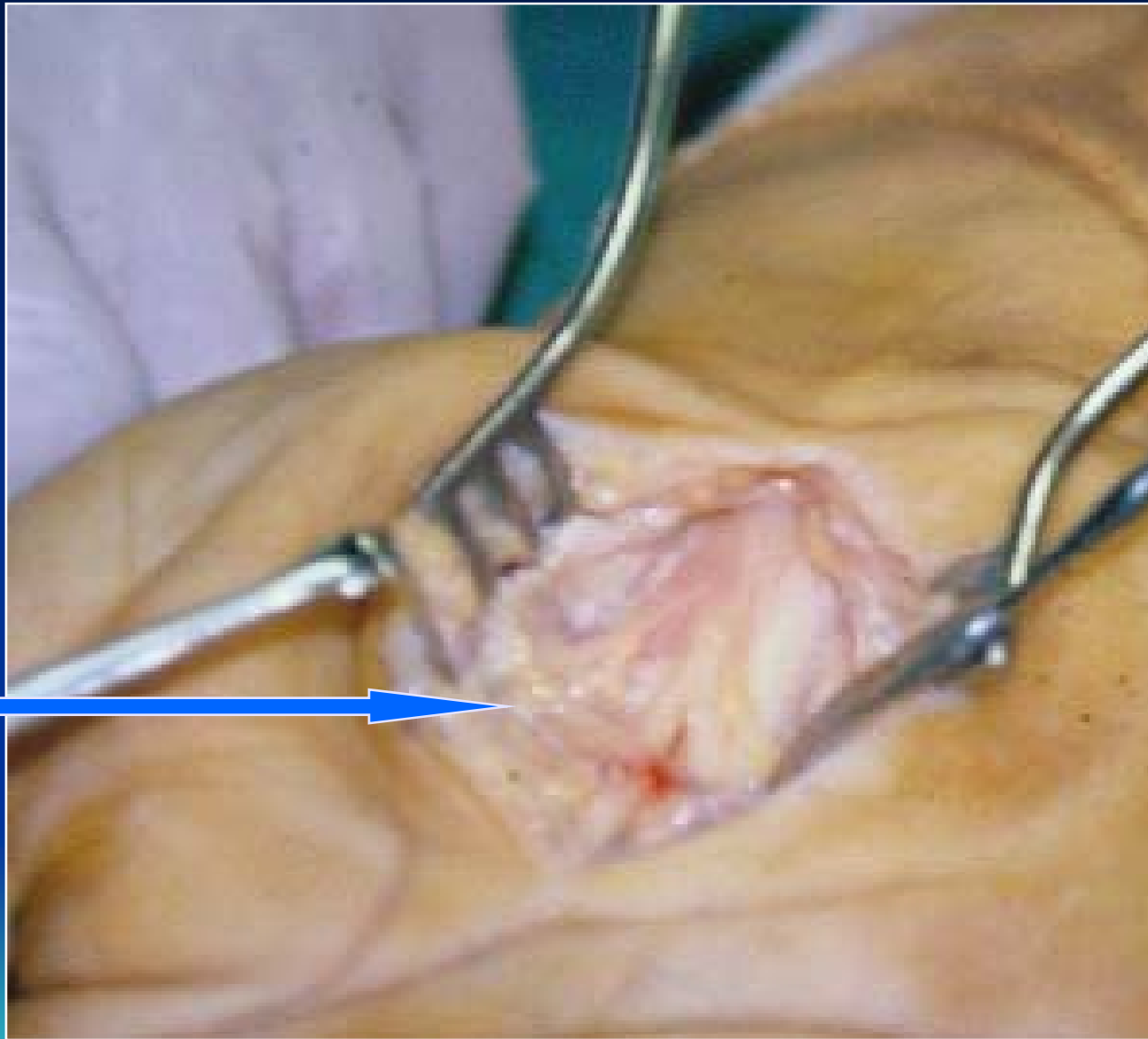


# Complications

- \* **Ulnar N. neuropraxia** 01
- \* **RSD** 01
- \* **Digital N neuropaxia** 01
- \* **Re exploration** 03 •

- + **Digital N. neuropraxia ???** •
- + **interpillar scarring**
- + **Digital N. Fibrosis**





# Tenderness Post Op

Site	Intensity	2W	4W	12W
<b>Scar</b>	<b>Mild</b>	<b>06</b>	<b>00</b>	<b>00</b>
	<b>Moderate</b>	<b>01</b>	<b>00</b>	<b>00</b>
	<b>Severe</b>	<b>00</b>	<b>00</b>	<b>00</b>
<b>Pillar</b>	<b>Mild</b>	<b>03</b>	<b>02</b>	<b>00</b>
	<b>Moderate</b>	<b>04</b>	<b>00</b>	<b>00</b>
	<b>Severe</b>	<b>00</b>	<b>00</b>	<b>00</b>

# Return to ADL

- \* 51 patient = 1 week
- \* 08 patients = 2 weeks
- \* 03 patients = 6 weeks

# Patient-Reported Symptoms

## Night pain

C/O	severity	Pre Op.	2 W P.O	4 W P.O	12 W P.O
Night pain	<b>Mild</b>	<b>04</b>	<b>07</b>	<b>01</b>	<b>00</b>
	<b>Moderate</b>	<b>23</b>	<b>05</b>	<b>00</b>	<b>00</b>
	<b>Severe</b>	<b>63</b>	<b>00</b>	<b>00</b>	<b>00</b>



# Patient-Reported Symptoms

## Numbness

C/O	Severity	Pre Op.	2 W P.O	4 W P.O	12 W P.O
Numbness	<b>Mild</b>	<b>04</b>	<b>11</b>	<b>06</b>	<b>02</b>
	<b>Moderate</b>	<b>23</b>	<b>00</b>	<b>00</b>	<b>00</b>
	<b>Severe</b>	<b>63</b>	<b>00</b>	<b>00</b>	<b>00</b>

# Conclusion

- \* **Simple, Safe & Successful.**
- \* **Needs training.**
- \* **Early recovery of hand function.**
- \* **Less tender scar and pillar pain.**
- \* **Temporary complications.**

Thank YOU